



## Potential Deleterious Effects Following the First Dose of Medroxyprogesterone Acetate as a Contraceptive in Cats

Ahmed I. Abdelgalil

Department of Surgery, Anesthesiology and Radiology, Faculty of Veterinary Medicine, Cairo University, Giza, P.O: 12211, Egypt

\*Corresponding Author: Ahmed I. Abdelgalil, E-Mail: [ismael7591@cu.edu.eg](mailto:ismael7591@cu.edu.eg)

### ABSTRACT

The aim of the present work was to investigate the deleterious effects of the first dose of medroxyprogesterone acetate (MPA) on the female genital system of cats. The study was conducted on 315 cats of different breeds who received their first dose (75 mg) of MPA as a contraceptive. Complete animal identification and stage of estrus were documented at admission. Physical, radiographic and ultrasonographic examinations were done on cats that expressed deleterious manifestations. All of the presented cats received an overdose of MPA during the estrous phase of the estrous cycle. Out of 315 cats who received their first dose of MPA, 27 (8.6 %) demonstrated varied deleterious effects related to the female genital system. Deleterious effects were reported within 15–90 days, including pyometra (n=10, 37.0%), endometritis (n=8, 29.6%), mammary gland hyperplasia (n=4, 14.8 %), cystic endometrial hyperplasia (n=3, 11.2%) and ovarian cyst (n=2, 7.4%). The incidence of these adverse effects increased with age. Persian cats seem to be more susceptible than other cat breeds. Long haired cat breeds seem to be more susceptible to adverse effects following injection of exogenous progestins (MPA) than short haired breeds (Siamese and Egyptian mau). Deleterious effects of MPA occurred following the first overdose. It is advised to use MPA as a contraceptive in the recommended dose during the inter-estrous or anestrus phase.

**Keywords:** Cat, Contraceptive, Mammary gland, Medroxyprogesterone acetate, Uterus.

### Original Article:

DOI:<https://dx.doi.org/10.21608/ja-vs.2023.207698.1223>

Received : 28 April, 2023.

Accepted : 27 July, 2023.

Published in October, 2023.

This is an open access article under the terms of the Creative Commons Attribution 4.0 (CC BY) International License. To view a copy of this license, visit:

<http://creativecommons.org/licenses/by/4.0>

*J. Appl. Vet. Sci.*, 8(4) : 01-05.

### INTRODUCTION

A cat is described as a long-day, seasonally polyestrous animal. During a breeding season, queens undergo repeated estrous cycles unless pregnancy or illness occurs (Little, 2012). The cat litter size ranges from 3.7 to 4.6 kittens (Sparkes *et al.*, 2006), the breeding life is about 10 years, and a queen can give birth to up to 100 kittens in her lifetime (Griffin, 2001). The overpopulation of cats around the world leads to suffering and euthanasia. So, an urgent need for safe and effective contraceptives was developed (Little, 2012).

Medroxyprogesterone acetate (MPA) is a synthetic progestin commercially available as a contraceptive for dogs and cats (Beijerink *et al.*, 2007; Beijerink *et al.*, 2008). It is a potent anti-ovulatory compound with progestational activity with much higher potency than endogenous progesterone (Romagnoli, 2015). The minimal effective dose of MPA is 2 mg/kg every 3–4 months or 3-5 mg/kg

every 5–6 months (Romagnoli and Concannon, 2003; Loretto *et al.*, 2005). Conservative doses of MPA depot are 2 mg/kg/5 months in cats (Romagnoli, 2006).

Overdose or prolonged MPA administration during stages of the estrous cycle can cause detrimental effects on cats (Kutzler and Wood, 2006; Keskin *et al.*, 2009). These effects include increased incidence of uterine pathology (endometritis, cystic endometrial hyperplasia (CEH), pyometra, and uterine neoplasms), increased incidence of mammary gland pathology (mammary gland hyperplasia, mammary neoplasms and increased secretion of prolactin), adrenocortical suppression, acromegaly, polydipsia, polyphagia, and diabetes mellitus (Romagnoli and Concannon, 2003; Plumb, 2005; Jacobs *et al.*, 2010). Several studies have been published reporting the adverse effects following repeated doses of MPA in cats (Plumb, 2005; Romagnoli, 2006; Roma Jacobs *et al.*, 2010), but there is no literature available

reporting the adverse effects following a single dose of MPA. The aim of this study was to report the deleterious effects on cats receiving the first and single dose of MPA as a contraceptive.

**MATERIALS AND METHODS**

An observational study was conducted on 315 female cats of different ages (mean±SD), body weights 3.5±1.2 kg (mean±SD) and breeds (Persian [n = 185], Turkish agora [n = 73], Siamese [n = 83], and Egyptian Mau [n = 14]) in the period between April 2017 and May 2022. Inclusion criteria included cats receiving a single first dose (75mg) of medroxyprogesterone acetate (MPA), which is routinely administered as a contraceptive in veterinary clinics in Egypt. These cats were either initially admitted to the clinic of the Faculty of Veterinary Medicine, Cairo University, or referred by veterinarians.

All cats’ owners were aware that their cats would be included for research purposes and signed a consent form indicating their approval. All institutional and international regulations for animal care and use were followed in the present study.

The collected data included the age and phase of the estrous cycle at the time of receiving MPA. All cats were monitored for about 3 months. The onset between receiving the first single dose of MPA and the appearance of adverse clinical signs was documented. The diagnosis of pathological conditions was based on complete physical, radiographic, and ultrasonographic examinations.

Physical examination included body temperature estimation and visual examination of vaginal discharges (colour and amount), mammary gland size and abdominal distention. Lateral abdominal radiographs were taken with exposure factors of 48–50 KVp, 3 mAs, and an 80–90 cm focal film distance.

Abdominal scanning was performed using a 5-7.5 MHz curvilinear probe (EXAGO ECM Co., Angouleme, France), a 6–8 MHz convex probe (Samsung Madison machine, Sonovet R3, Korea), and 7.5–9 MHz microconvex transducer (Edan Dus 60, USA). Ovariohysterectomy was performed following the diagnosis of cystic endometritis and pyometra and the excised ovaries and uterus were visually evaluated.

**RESULTS**

Out of 315 cats who received their first and single dose (75 mg) of MPA, 27 cats (8.6 %) demonstrated varied deleterious effects related to the female genital system. These cats were of different breeds (Persian [n = 14], Turkish agora [n = 6],

Siamese [n = 5], and Egyptian Mau [n = 2]. The mean age of cats at the time of receiving their first dose of MPA was 5.7–1.9 years. All cats received MPA during the estrous phase of the estrous cycle to overcome the annoying breeding behaviour. The interval between receiving MPA and the appearance of adverse clinical signs ranged from 15 to 90 days. These adverse effects included pyometra (n = 10, 37.0%), endometritis (n = 8, 29.6%), mammary gland hyperplasia (n = 4, 14.8 %), cystic endometrial hyperplasia (CEH, n = 3, 11.2%), and ovarian cyst (n = 2, 7.4%). The distribution of pathological conditions related to the female genital system following the first administration of MPA is demonstrated in Table 1. The age distribution of these deleterious effects is demonstrated in Fig. 1.

Table 1: Distribution of cats with deleterious effects following the first administration of medroxy progesterone acetate.

Deleterious Effect	No. (%)	Breed	Time (days) since MPA* injection	Remarks
Endometritis	8 (29.6 %)	Persian Cat (n=4) Turkish agora (n=2) Siamese (n=1) Egyptian Mau (n=1)	20-45 d.	Associated with vaginitis
Cystic endometrial hyperplasia	3 (11.1 %)	Persian Cat (n=2) Turkish agora (n=1)	45-90 d.	2 Pyometra
Pyometra	10 (37.0 %)	Persian Cat (n=5) Turkish agora (n=2) Siamese (n=2) Egyptian Mau (n=1)	30-90 d.	7 Open pyometra with endometritis and vaginitis 3 closed pyometra
Ovarian cyst	2 (7.4 %)	Persian Cat (n=1) Siamese (n=1)	60, 90 d.	
Mammary gland hyperplasia	4 (14.8 %)	Persian Cat (n=2) Turkish agora (n=1) Siamese (n=1)	15-60 d.	Vaginitis
Total	27 (100.0 %)			

\*MPA: medroxy progesterone acetate

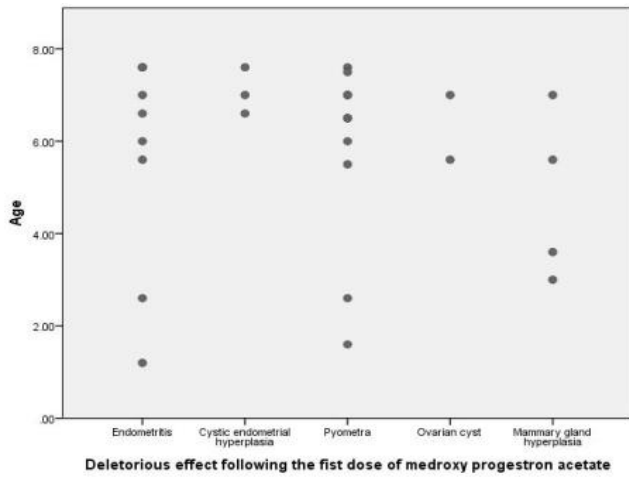


Fig.1: Deleterious effects following the first dose of medroxyprogesterone acetate in cats in relation to age.

The most prevalent clinical signs in cats presented with endometritis were decreased appetite, loud moaning, arched back and turbid vaginal discharges (mixed with blood in 3 cats). Radiographically, a radio-dense mass was detected cranial to the urinary bladder in 4 cats. Ultrasonography was helpful in diagnosing cats with endometritis, where a thick hypoechoic uterine wall with anechoic uterine content was seen.

Cats with CEH were presented with a decreased appetite, polyurea, and polydipsia. One cat had vaginal discharges, while another cat was associated with endometritis. Radiographic diagnoses included the presence of a radio-dense mass cranial to the urinary bladder (one cat). Ultrasonographically, cats with CEH showed a thickened uterine wall with multiple pockets containing anechoic fluid.

Pyometra was manifested clinically by fever (>39.8°C), decreased appetite, polyurea, polydipsia, and lethargy. Seven cats were presented with open pyometra (purulent bloody discharge was drained from the vagina). Three cats were presented with closed pyometra (marked abdominal distension). Radiographically, a radio-dense sac-like structure was seen filling the abdomen, resulting in cranial displacement of the abdominal viscera (Fig. 2a). Ultrasonography revealed a segmentally distended fluid-filled uterus with a thickened hypoechoic uterine wall and characteristic thick hyperechoic bands dividing the uterus into multiple pockets containing hypoechoic pus (Figs. 2b-e).

An ovarian follicular cyst was diagnosed in two cats and they did not express clinical or radiographic abnormalities. It was diagnosed in one cat during routine ovariohysterectomy (Fig. 3a,c) and incidentally during ultrasonographic examination in another cat (1cm anechoic sac).

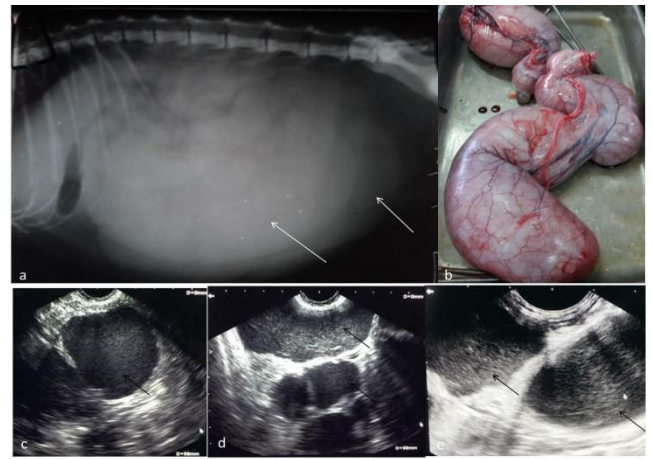


Fig. 2: (a) lateral abdominal radiographic view showing a radio-dense mass cranial to the urinary bladder (white arrows). (b) Photographic view of uterus after ovariohysterectomy showing severely enlarged uterus and filled with pus (pyometra). (c, d & e) demonstrated segmentally distended uterus with hypoechoic pus (black arrows) and a characteristic thick hyperechoic bands dividing the uterus into multiple pockets indicating pyometra.

Mammary gland hyperplasia was detected as a painless, doughy, massive enlargement of the mammary gland. These enlargements had a sudden, rapid onset in one cat and progressed slowly over 60 days in three cats (Fig. 3b). Masses were bilaterally symmetrical with sharply circumscribed and clearly delineated borders, including the abdominal and inguinal mammary glands. The skin over the masses was tense, stretched, and erythematous, with marked alopecia. Radiographically, a homogenous enlargement of the mammary gland was detected with no evidence of lysis or sclerosis. Ultrasonographic examination revealed homogenous enlarged mammary glandular tissue without evidence of malignancy.

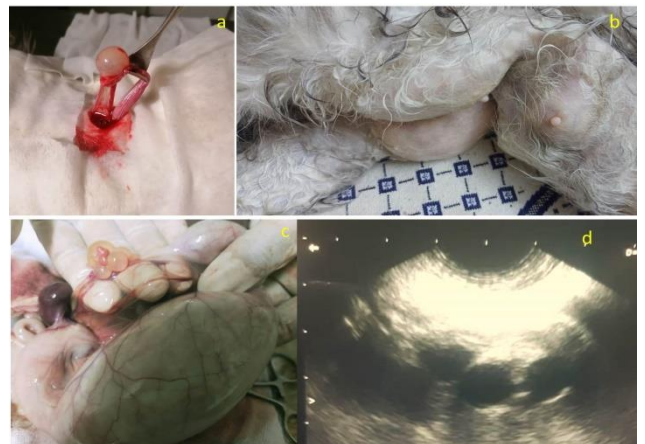


Fig. 3: a&c) showed cystic ovaries alone (a) and associated with pyometra (c). b) Showed mammary gland hyperplasia in 5 years Persian queen. d) Ultrasonographic scan revealed presence of multiple pockets containing anechoic fluid indicating cystic endometritis.

## DISCUSSION

The present study demonstrated that 27 cats presented with various deleterious effects following the first single dose of medroxyprogesterone acetate (MPA). Fourteen (52%) of the presented cats were Persians, which may be correlated with the overrepresentation of this breed in the current study or may be due to the increased sensitivity of Persian cats to progestin. Little, 2012 reported that longhair queens exhibit irregular estrous cycles even during long daylight periods, while shorthair queens, as a Siamese breed, exhibit regular estrous cycles regardless of daylight length. The irregular estrus cycle may lead to changes in the hormonal profile of long-haired breeds such as Persian cats, which predispose them to the rapid deleterious effects of progestin injection.

In the present study, the incidence of adverse effects related to MPA increased with age, while previous studies have reported an increase in the risk of uterine or mammary gland disease at a young age (6–20 months) (Romagnoli and Concannon, 2003; Loretto *et al.*, 2005). Feldman and Nelson, (2004) reported that the first estrus of Persians and related breeds may occur at 18 months of age or older, and sexual maturity may occur at 2–3 years of age. Long haired breeds represent 73.6 % of the presented cats and may have an effect on the time of administration of the first dose of MPA. The distribution of deleterious effects following administration of MPA in relation to the age of cats revealed that endometritis and pyometra are closely correlated.

Injection of MPA during the estrus phase of the estrus cycle increased the incidence of its side effects, which could be attributed to the role of oestrogens in priming and stimulating the synthesis of progesterone receptors in the endometrium and mammary glands leading to hypersensitivity of these tissues to endogenous and exogenous progesterone. Similar findings and explanations were mentioned in several previous studies (De Bosschere *et al.*, 2002; Loretto *et al.*, 2005; Max *et al.*, 2015). The MPA dose (75 mg) received by the presented cats exceeds the recommended dose for cats. Overdosage of MPA may play a role in the evolution of deleterious effects (Loretto *et al.*, 2005).

The reported CEH, pyometra and CEH-pyometra complex were the most frequent sequels to progesterone stimulation of the endometrium which is consistent with previous studies (Johnston, 2001; Feldman and Nelson, 2004). Progesterone and synthetic progestins stimulate uterine gland secretion, causing hyperplasia, hypertrophy, and consequently the formation of cysts of varying sizes which may predispose the uterus to infection by normal vaginal

flora resulting in pyometra (De Cock *et al.*, 2002; Kim and Kim, 2005; Keskin *et al.*, 2009).

The follicular cysts reported in this study may be due to the action of synthetic progestins as potent anti-ovulatory compounds where the increase in progestational activity inhibits the luteinizing hormone surge necessary for ovulation, leading to follicular cyst formation (Keskin *et al.*, 2009). The mammary gland is a target organ for MPA where progestins induce hyperplastic ductular changes in the mammary gland and hypersecretion of growth hormone of mammary origin which lead to mammary gland hyperplasia and neoplasia (Loretto *et al.*, 2005; Skorupski *et al.*, 2005; Keskin *et al.*, 2009; Jacobs *et al.*, 2010; Ochota *et al.*, 2014).

In the present study, deleterious effects following MPA administration were reported until 90 days after administration which doesn't rule out the occurrence of their adverse effects after 90 days. It has been reported that MPA can maintain an effective circulating level for 6 months following administration (Romagnoli, 2002; Keskin *et al.*, 2009; Romagnoli, 2015; Papich, 2021).

The main limitation of this study was the absence of a hormonal profile in the presented cats before and after MPA administration. Administration of MPA in the recommended dose in an inter-estrus period or in seasonal anestrus is highly recommended. Further studies should be directed to investigate the adverse effects of MPA following administration of the recommended dose.

## CONCLUSION

Deleterious effects may occur following the first dose of MPA if taken in overdosage. It is advised to use MPA as a contraceptive in the recommended dose during the inter-estrus or anestrus phase.

### Conflicts of interest

The author declares no conflict of interests

## REFERENCES

- BEIJERINK, N.J., BHATTI, S.F., OKKENS, A.C., DIELEMAN, S.J., MOL, J.A., DUCHATEAU, L., VAN HAM, L.M. L., and KOOISTRA, H.S., 2007. Adenohypophysial function in bitches treated with medroxyprogesterone acetate. *Domest Anim Endocrinol*, 32: 63–78. <https://doi.org/10.1016/j.domaniend.2005.12.008>
- BEIJERINK, N.J., BHATTI, S.F., OKKENS, A.C., DIELEMAN, S.J., DUCHATEAU, L., and KOOISTRA, H.S., 2008. Pulsatile plasma profiles of FSH and LH before and during medroxyprogesterone acetate treatment in the bitch. *Theriogenology*, 70: 179–185. <https://doi.org/10.1016/j.theriogenology.2008.03.004>



- DE BOSSCHERE, H., DUCATELLE, R., VERMEIRSCH, H., SIMOENS, P., and CORYN, M., 2002.** Estrogen- $\alpha$  and progesterone receptor expression in cystic endometrial hyperplasia and pyometra in the bitch. *Animal Reproduction Science*, 15; 70: 251-259. [https://doi.org/10.1016/S0378-4320\(02\)00013-1](https://doi.org/10.1016/S0378-4320(02)00013-1)
- DE COCK, H., DUCATELLE, R., TILMANT, K., and DE SCHEPPER, J., 2002.** Possible role for insulin like growth factor-I in the pathogenesis of cystic endometrial hyperplasia pyometra complex in the bitch. *Theriogenology*, 57: 2271-2287. [https://doi.org/10.1016/s0093-691x\(02\)00856-7](https://doi.org/10.1016/s0093-691x(02)00856-7)
- FELDMAN, E.C., and NELSON, R.W., 2004.** Feline Reproduction. In *Canine and Feline Endocrinology and Reproduction*. 3rd ed. Missouri: Saunders. pp. 1016-1044. <https://www.amazon.com/Canine-Feline-Endocrinology-Reproduction-Third/dp/0721693156>
- GRIFFIN, B. 2001.** Prolific cats: the estrous cycle. *Comp Contin Edu Pract Vet*. 23:1049. [https://www.researchgate.net/publication/285707118\\_Prolific\\_Cats\\_The\\_Estrous\\_Cycle](https://www.researchgate.net/publication/285707118_Prolific_Cats_The_Estrous_Cycle)
- JACOBS, T.M., HOPPE, B.R., POEHLMANN, C.E., FERRACONE, J.D., and SORENMO, K.U., 2010.** Mammary adenocarcinomas in three male cats exposed to medroxyprogesterone acetate (1990-2006). *Journal of Feline Medicine and Surgery*, 12: 169-174. <https://doi.org/10.1016/j.jfms.2009.08.004>
- JOHNSTON, S.D., ROOT KUSTRITZ, M.V., and OLSON, P.N.S., 2001.** Prevention and termination of feline pregnancy. In Johnston, SD, Root Kustritz, MV, Olson, PNS (Eds.). *Canine and Feline Theriogenology*, Philadelphia, USA: WB Saunders. pp. 447-452.
- KESKIN, A., YILMAZBAS, G., YILMAZ, R., OZYIGIT, M., and GUMEN, A., 2009.** Pathological abnormalities after long-term administration of medroxyprogesterone acetate in a queen. *Journal of Feline Medicine and Surgery*, 11: 518-521. <https://doi.org/10.1016/j.jfms.2008.10.006>
- KIM, K.S., and KIM, O., 2005.** Cystic endometrial hyperplasia and endometritis in a dog following prolonged treatment of medroxyprogesterone acetate. *Journal of Veterinary Science*, 6: 81-82. <http://dx.doi.org/10.4142/jvs.2005.6.1.81>
- KUTZLER, M., and WOOD, A., 2006.** Non-surgical methods of contraception and sterilization. *Theriogenology*. 66:514. <https://doi.org/10.1016/j.theriogenology.2006.04.014>
- LITTLE, SE. 2012.** Female Reproduction. *The Cat*. 1195-227. <https://doi.org/10.1016%2FB978-1-4377-0660-4.00040-5>
- LORETTI, A.P., ILHA, M.R., ORDAS, J., LAS, D.E., and MULAS, J.M., 2005.** Clinical, pathological and immunohistochemical study of feline mammary fibroepithelial hyperplasia following a single injection of depot medroxyprogesterone acetate. *Journal of Feline Medicine and Surgery*, 7: 43-52. <https://doi.org/10.1016/j.jfms.2004.05.002>
- MAX, A., JURKA, P., DOBRZYŃSKI, A., and RIJSSELAERE, T., 2015.** Non-surgical contraception in female dogs and cats. *Acta Scientiarum Polonorum Zootechnica*, 14: 3-18.
- OCHOTA, M., NOWAK, M., DZIECIOL, M., and NIZANSKI, W., 2014.** Mammary adenocarcinoma after 10-year medroxyprogesterone acetate supplementation in an ovariectomized cat. *Pakistan Veterinary Journal*, 34: 406-409. [http://www.pvj.com.pk/pdf-files/34\\_3/406-409.pdf](http://www.pvj.com.pk/pdf-files/34_3/406-409.pdf)
- PAPICH, M.G. 2021.** Medroxyprogesterone Acetate. In *Papich Handbook of Veterinary Drugs (Fifth Edition)*, Elsevier, Netherlands, p: 560-556. <https://doi.org/10.1016/B978-0-323-70957-6.00326-5>
- PLUMB, D.C. 2005.** Medroxyprogesterone acetate. In *Veterinary drug handbook*. 5th ed. Stockholm, WI: Pharmavet. [https://en.wikipedia.org/wiki/Medroxyprogesterone\\_acetate](https://en.wikipedia.org/wiki/Medroxyprogesterone_acetate)
- ROMAGNOLI, S. 2002.** Clinical use of hormones in the control of reproduction in bitches and queens. *Proceedings of the Veterinary Sciences Congress (SPCV)*, Oeiras, Portugal. pp. 162-166.
- ROMAGNOLI, S., and CONCANNON, P.W., 2003.** Clinical use of progestins in bitches and queens: a review. In *Recent Advances in Small Animal Reproduction*. International Veterinary Information Service, Ithaca, New York, USA. 1206, 0903. <https://www.ivis.org/library/recent-advances-small-animal-reproduction/clinical-use-of-progestins-bitches-and-queens-a-0>
- ROMAGNOLI, S. 2006.** Control of Reproduction in Dogs and Cats: Use and Misuse of Hormones. The 31<sup>st</sup> Congress of the World Small Animal Veterinary Association World Congress Proceedings, Prague, Czech Republic.
- ROMAGNOLI, S. 2015.** Progestins to control feline reproduction: Historical abuse of high doses and potentially safe use of low doses. *Journal of Feline Medicine and Surgery*, 17(9):743-52. doi: 10.1177/1098612X15594987. <https://doi.org/10.1177/1098612x15594987>
- SKORUPSKI, K.A., OVERLEY, B., SHOFER, F.S., GOLDSCHMIDT, M.H., MILLER, C.A., and SORENMO, K.U., 2005.** Clinical characteristics of mammary carcinoma in male cats. *Journal of Veterinary Internal Medicine*, 19: 52-55. [https://doi.org/10.1892/0891-6640\(2005\)19%3C52:ecomci%3E2.0.co;2](https://doi.org/10.1892/0891-6640(2005)19%3C52:ecomci%3E2.0.co;2)
- SPARKES, A.H., ROGERS, K., and HENLEY, W.E., 2006.** A questionnaire-based study of gestation, parturition and neonatal mortality in pedigree breeding cats in the UK. *J Feline Med Surg.*, 8:145. <https://doi.org/10.1016/j.jfms.2005.10.003>

**How to cite this article:**

Ahmed I. Abdelgalil, 2023. Potential Deleterious Effects Following the First Dose of Medroxyprogesterone Acetate as a Contraceptive in Cats. *Journal of Applied Veterinary Sciences*, 8 (4): 01-05.

DOI:<https://dx.doi.org/10.21608/javs.2023.207698.1223>