



Detergent Maceration: A Convenient Skeleton Preparation Technique for Teaching and Demonstration of Veterinary Anatomy

Ashraf Zaman Faruk* and Shonkor Kumar Das

Department of Anatomy and Histology, Faculty of Veterinary Sciences, Bangladesh Agricultural University, Mymensingh-2202, Bangladesh.

*Corresponding Author: Ashraf Zaman Faruk, E-Mail: faruk.unibd@yahoo.com

ABSTRACT

The current study investigates to develop a convenient technique for preparation of a dog skeleton without any unpleasant smell, cracking, crumbling or discoloration of bones by using a combination of commercially available detergent and Hydrogen peroxide (H₂O₂). Specimens were skinned and immersed in a pre-heated 10-liter detergent solution at 50°C to 60°C for 2-3 hours then left for 12 hours. Maceration was deemed completed when any remaining soft tissue was easily removed under running tap water or by soft brush. Then the bones were kept for bleaching with 3% H₂O₂ for 24-48 hours and allowed to dry properly in the sun. It is shown that the detergent maceration was remarkably faster compared to the traditional burial, insect, hot or cool-water methods, which requires up to several days. In this entire process, skeletons were prepared and installed in correct conformation in only about 92 hours (less than four days). In contrast, the whole maceration was completed in 15 hours (boiling and cooling). On the other hand, the longest time was taken for bleaching and drying purposes, which were 2 days, respectively. The method investigated here for the preparation of skeletal materials in an essentially odorless way, which has shown to be more convenient (faster, easier, safer, and cheaper) compare to previous models in the fields of veterinary anatomy. We believe this project's result will help improve the preparation and preservation technique of skeletons for gross anatomical studies in veterinary institutions.

Keywords: Detergent, Dog Skeleton, Hydrogen peroxide (H₂O₂), Maceration.

Original Article:

DOI:<https://dx.doi.org/10.21608/javs.2022.158955.1175>

Received :28 August, 2022.

Accepted :15 November, 2022.

Published in January, 2023.

This is an open access article under the term of the Creative Commons Attribution 4.0 (CC-BY) International License . To view a copy of this license, visit:

<http://creativecommons.org/licenses/by/4.0/>

J. Appl. Vet. Sci., 8(1) : 11-17.

INTRODUCTION

Skeleton is the hard structural framework that supports the body, allows movement, makes blood cells, stores minerals, and protects the soft tissues of an animal (Getty, 1975; Ghosh, 2006). The skeleton may be divided primarily into three parts: the axial skeleton, which comprises the vertebral column, ribs, sternum, and skull; the appendicular skeleton, which includes the bones of the limbs, and the splanchnic skeleton, which consists of certain bones developed in the substance of some of the viscera or soft organ, e.g., the os penis of the dog and the os cordis of the ox (Getty, 1975; Kardong, 2002).

Preparation of a skeleton for osteological examination is a common learning tool in the fields of veterinary anatomy, zoology, and anthropology, though it is often necessary during the course of certain forensic and archeological studies (Olson, 2003). Skeletons have been prepared for several decades for

use in identifying species and exploring animals' life history including diet, behavior, and habitat (Sullivan and Romney, 1999). Particularly articulated dry skeletons are useful in anatomical research, ranging from phylogenetic investigations to age and growth analyses to functional morphology (Bemis *et al.*, 2004).

According to the Leiden University Laboratory for Human Osteoarchaeology (2019), Bones contain information about people's lives such as where they came from, their age at death, and which diseases they suffered from. So the study of the animal condition would be impossible without using skeletal material, especially in human and faunal gross anatomy. As a result, the preparation of animal and birds skeletons are essential and important teaching tool in academic institutions, museums, and anatomy halls to enhance a better understanding of anatomy, which is considered the most important course in the preclinical stages

(Greene *et al.*, 1993; Zaneb and Stanek, 2008; Kempa, 2016). Therefore, from a full skeleton displayed in an anatomy laboratory or a biological class to individual bones used in comparative and forensic contexts.

In addition, the skeleton gives students a hands-on method for learning bone names and locations and a visual tool to relate bone and joints to muscle structure (Greene *et al.*, 1993). So, the modern skeleton system serves as didactic equipment in educational institutions and as exhibits in museums, hunting trophies, and scientific research materials (Kempa, 2016). However, teaching skeletal systems will be more interesting if using original preserved material or specimens compared to pictures and books. Direct virtual observation plays an important role in students' understanding of biological phenomena. Moreover, the learning process strongly influences students' mental models of a biological phenomenon (Prokop *et al.*, 2007).

Different practices and procedures of maceration techniques have been described in the literature, including burial under-ground, insect decomposition, water maceration, enzymatic maceration, chemical maceration, and physical maceration (Allen and Neill, 1950; Fenton *et al.*, 2003; Maries *et al.*, 2004; Simonsen *et al.*, 2011; Leeper, 2015; Soon *et al.*, 2015). The main purpose of all these techniques is to clean the remaining soft and adipose tissue from the bone to prepare complete skeletal tissues (Couse and Connor, 2015; Leeper, 2015). In order to have a good visualization of the skeleton during the examination, it is important to process and clean the bone effectively with minimal damage. Though, several acceptable macerating techniques are available (Mann and Berryman, 2012), no universal standardized protocols describe which technique or combination of techniques are best to use in a skeleton preparation setting (Leeper, 2015). Therefore, most laboratories often employ their own standardized techniques and methods according to their experience. The overall success of a macerating technique is determined by the time efficiency, required resources, and the final desired result (Maries *et al.*, 2004; Gofur and Khan, 2010; Simonsen *et al.*, 2011).

The purpose of this study was to prepare a real skeleton model of a canine pariah dog to teach the osteology and comparative anatomy of bones in the veterinary teaching profession and also for demonstration. To my knowledge, preparing a real dog skeleton model using a combination of detergent and H₂O₂ maceration technique has not been previously studied or prepared in our area. Therefore, we expect

that the findings of this research will bridge the gap of information on the skeleton preparation of canine species and determine the time involved in the preparation.

MATERIALS AND METHODS

Ethical approval

This present experiment was approved and performed according to the guidelines of Animal Welfare and Experimentation Ethics Committee, Bangladesh Agricultural University, Mymensingh, Bangladesh [AWEEC/BAU/2019(36)].

This experiment was performed to prepare a real skeleton model of a local pariah dog where approximately 320 individual bones were rigidly articulated. Among all the species, the local pariah dog was selected based on the following criteria: Firstly, laboratory requirement: The Anatomy lab at the Department of Anatomy and Histology of Bangladesh Agricultural University was in high demand for this kind of model to take benefit from teaching and educational purposes. Secondly, a consistent increase in pet animal practice and research. Thirdly, a dog is an animal that is very easy to obtain from the locality.

Two adult euthanatized (dead) dogs (both male and female) have been collected from the Veterinary Teaching Hospital of Bangladesh Agricultural University, which were previously sacrificed for different practical interventions. Euthanization was done by injecting a saturated magnesium sulphate (MgSO₄) intravenously at 2 ml per kg body weight.

In this experiment, skeleton preparation was performed using the water boiling method, with locally available detergent (Surf Excel) used as a degreasing agent and hydrogen peroxide (H₂O₂) used for bleaching the bones. Special super-adhesive glue, a drilling machine, and copper wires of different diameters were used to fix the bones in their right anatomical location and eventually install the model on a specified wooden plate for display. The following steps did this and the time used in each step for different bones was accurately estimated:

1. Skinning, Evisceration, and Cleaning

Removed the skin and performed evisceration (removal of viscera and internal organs), then cleaned thoroughly with tap water (Fig. 1).

2. Defleshing

Removed the fleshy mass along with adipose tissue from the bones up to the maximum extent as possible by using a knife, scalpel, scissors, or pliers, so that the bones were visible.

3. Separating bones/body parts

Separated the animal body into different parts: fore-limb, hindlimb, skull with vertebrae, ribs & sternum, and pelvic bone (Fig. 1). Fore-limb, hindlimb, and pelvic bone are packed in a nylon mesh with an identified marker to avoid mixing. A thin wire (1 mm) was driven through the vertebral column to the skull to keep the natural order of vertebrae from skull to tail. Ribs and sternum are tightly knotted serially by a copper wire (0.5 mm) *in situ* position of the skeleton and gently pulled away from the backbone.

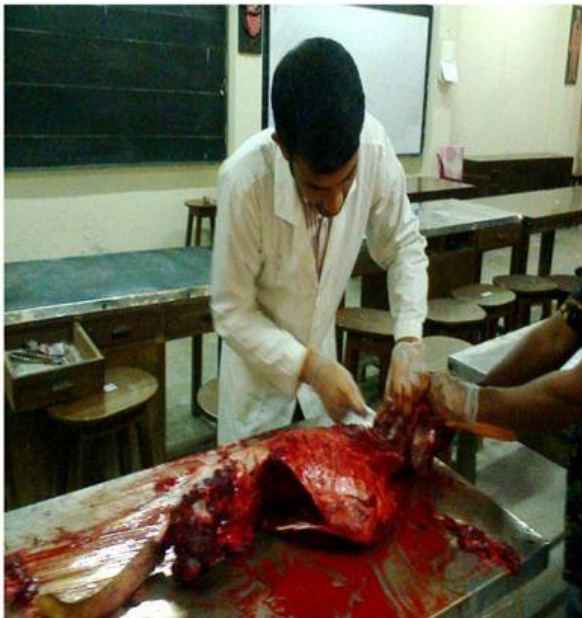

Fig.1: Skinning, Evisceration, and Separation of different body parts.

4. Boiling the separated bones

Bones are boiled in a mixed solution of washing powder detergent and tap water (300-350gm of surf excel mixed in 10-liter tap water) at 50°C to 60°C for a maximum of 3 hours and left in it for 12 hours to loosen the flesh around the bones in accordance with **Maris *et al.*, 2004** and **Mahon *et al.*, 2021**. Unlike boiling, ribs and sternum are only manually cleaned and allowed for bleaching and sundry properly to prevent damage and retain their original shape, density and firmness.

Cooking of skeletons in hot water must be done carefully and checked frequently. Boiling of the skeleton can destroy disease-causing organisms, but rigorous boiling can cause damage and shrinkage of the bones. Larger or heavier bones can be gently boiled and smaller or more delicate bones should be gently simmered to prevent damage and shrinkage.

5. Further cleaning and bleaching

After boiling, all bony segments are taken out and separated from the joints carefully. Then again cleaned, all the remaining flesh and tissue were

thoroughly washed with running tap water. Later, bones are dipped into a 3% hydrogen peroxide (H₂O₂) bleaching solution for 24-48 hours according to the size of bones to avoid further decomposition of microorganisms and improve the whitening appearance of bones.

6. Drying

The bones are exposed to direct sunlight for 24-48 hours until they are completely dry as described by **Gofur and Khan (2010)** and **Rowley (2015)**. Finally, 100 ml varnish and 200 ml thinner were mixed and sprayed on each bone properly to get a shiny appearance.

7. Assembling the bones into skeleton

Finally, the bones were articulated and raised into the skeleton *in situ* position as demonstrated by **Rowley (2015)** and **Atabo *et al.*, (2019)** (Figs. 2 A and B). The skeleton was mounted on a wooden base plate, length: 92 cm, width: 40 cm, two stainless steel rods (height: 70 cm and 62 cm, thickness: 6 mm) were used to carry the skeleton, the first one at the atlas of cervical vertebrae and the second one at the level of last lumbar vertebrae which gave the desired strength and support. Copper wire (0.5 mm) is used to tie the backbone to the rods.

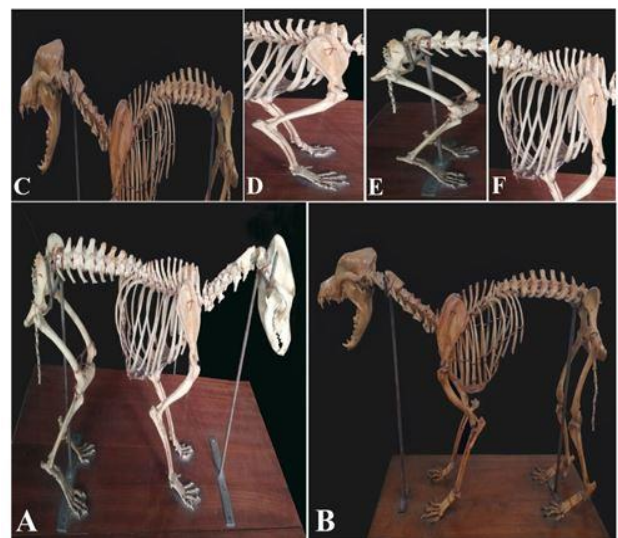


Fig.2: A. Dog (*Canis domestica*) skeleton (Male) without varnish; B. Dog (*Canis domestica*) skeleton (Female) with varnish; C. Vertebrae and Skull; D. Fore-limbs; E. Hind-limbs and E. Dog skeleton; F. Ribs and sternum.

RESULTS

Literally, in this experiment about 320 individual bones of the axial and appendicular skeleton were correctly installed and the time required in each step of this preparation was accurately estimated (Tables 1 and 2). In our experiment, carcasses were decomposed through the boiling of detergent containing water for about 3 hours and it was then cooled for 12 hours to remove as much muscle, tendon,

soft tissue, and other flesh as possible, also known as degreasing. After boiling and cooling, the bone specimens were cleaned manually with a soft brush or forceps which took about 4 hours to employ. Bleaching was then performed in 3% H₂O₂ for 24 to 48 hours depending on the size and nature of the bones. After that bones were dried absolutely by using sun rays for about 2 days. As inside the cavity of the bones, there may be a possibility of attaching some gristle or grease materials, but once completely dried through the sun, it might be mummified and prevents further microbial decomposition of bones. A mixture of varnish and thinner (100 ml and 200 ml) was used to get a nice bonny color and this step took 1 hour to complete. The overall process took 92 hours (less than 4 days), where cooling and drying were the most time-consuming steps, accounting for 65% of the total time employed in this preparation process.

Table 1: Time required for preparing skeleton in each step

Steps	Requires time
Skinning and evisceration of carcass	As quick as possible
Defleshing of carcass	As quick as possible
Decomposition of carcass	
Boiling	3 hours
Cooling	12 hours
Clearing	4 hours
Bleaching	24-48 hours
Drying	2 days
Varnishing	1 hour
Articulation and rising of skeleton	As the time required
Total estimated time	92 hours

Table 2: Time required for different types of bone in skeleton preparation

Type of Bone	Time required		
	Boiling (hour)	Degreasing (hour)	Bleaching (hour)
Long bones	3	12	48
Vertebrae	3	12	48
Skull	3	12	48

Sesamoids, phalanges	2	12	24
Ribs, sternum,	-	-	24

In this study, long bones, vertebrae and skull were boiled, degreased, and bleached for 3, 12, and 48 hours respectively, while sesamoid and phalanges bones were only kept for 2, 12, and 24 hours, respectively. The ribs and sternum were only bleached in H₂O₂ for 24 hours without boiling and degreasing (Table 2). Skinning, evisceration, and defleshing of the carcass should be accomplished as quickly as possible; however, it is considered that the quality of decomposition is closely related to these steps. So care must be taken for proper skinning, evisceration, and defleshing of carcasses to get a better result from the successive steps. To get accurate conformation of the skeleton, bones' articulation and rising were performed as required.

The vertebral column was shaped by inserting a metal rod, 115 cm long and 4 mm in diameter, into the vertebral canal (marrow cavity) of the sacral, lumbar, thoracic, and cervical vertebrae up to the foramen magnum of the skull and maintained an accurate curvature of the spine. Furthermore, super adhesive glue connected the articular surfaces from the first cervical to the first sacral vertebra. The coronoid process of the mandible and zygomatic bone of the skull was drilled on both sides, and knots were made to articulate both bones *in situ* by inserting the copper wire into the respective holes. By tying a knot with the skull's occipital condyle and the cranial part of the atlas wings, the skull was secured to the vertebral column (Fig. 2C).

The caudal articular process of 3rd sacrum and cranial articular process of 1st coccygeal (caudal vertebrae) bone were drilled on both sides and articulated this sacrococcygeal joint by using copper wire. The coccygeal (caudal) vertebrae were drilled medially as possible, a thin wire passed through them and super adhesive glue was also applied to fix them properly. A thin, non-corrosive copper wire (0.5 mm) fixed the ribs and sternum to the thoracic vertebrae. For example, a small hole was drilled at the head of each pair of ribs and the corresponding attached point to its associated vertebrae (Fig. 2F).

The bones of the fore and hind limbs were mounted, respectively, by placing them in exact

conformation. The holes on the proximal and distal ends of the long bones were placed sequentially to ensure the desired angle and placement. Then drill into the bones' articulation joints until reaching the rod's required diameter. The iliac and sacral wings were drilled on both sides and fixed at the sacroiliac joint with a copper wire through the holes. The femur was attached to the pelvic bone at the acetabulum by drilling the head of the femur and tying it with copper wire through the holes (Fig. 2E).

The tarsal bones of the limbs were assembled and articulated *in situ* using super adhesive glue and a plastic hock. The left and right medial epicondyles and condyles of both femur and tibia were drilled in the appropriate position and articulated by inserting the copper wire into the holes. The medial and lateral malleolus, talus, and calcaneus were drilled, respectively, and copper wire was passed through to articulate them. To fix them properly, a hole was drilled into the distal part of the 4th tarsal and the base of the 5th metatarsal (proximal part) bones. The metatarsus and phalanges were glued at the appropriate angle, accounting for the distance between the tarsus and the base. The forelimb bones were articulated similarly to the hindlimb bones, and both scapulae were attached to the ribs with plastic band hooks to maintain proper alignment (Fig. 2D).

DISCUSSION

This present study revealed a new preparation technique for dog skeletons that might be helpful in veterinary teaching methods and demonstrations. The adult dog was used in this experiment to avoid the risk of bone softening and shrinkage because boiling can cause bone damage (Vanceleave, 2010). Overall this experiment was performed in seven consecutive steps, where all steps were conducted without any complications related to the bones: their shapes, rigidity, density, and color, which are also compatible with the study of Habib and Ali, (2019). It took 92 hours overall to prepare the entire process without damaging any delicate parts of the skeleton (Table 1), which is relatively easy and less time-devouring than other researchers reported earlier (Greene *et al.*, 1993; Gofur and Khan, 2010).

In our experiment, long bones, vertebrae and skull were boiled, degreased and bleached for 3, 12 and 48 hours, respectively, while sesamoid and phalanges bones were kept for 2, 12, and 24 hours respectively. But instead of boiling and degreasing the ribs and sternum, only bleaching was done for 24 hours in H₂O₂. Furthermore, Hussain *et al.*, (2007) and Allouch (2014) both reported that small animals (ovine and canine) must be boiled for 3-4 hours, degreasing for 3-7 days and bleaching for 2 days, which did not completely reflect our methods. Tefera (2011) also

mentioned a recommended processing time (in days) for preparing dry skeletons: approximately 28.25 days for ovine and canine animals.

On the other side, detergents' health and safety risks are very low compared to other forms of maceration (Maries *et al.*, 2004) and less time devouring methods than chemical and insect maceration (Soon *et al.*, 2015). All bones are firmly attached to flesh, mostly made of protein. Detergents contain some bleaching ingredients (Uhre *et al.*, 2015; Ajayi *et al.*, 2016), which attack and oxidize protein bonds within soft tissues and cause these bonds to break down (Mann and Berryman, 2012). However, maceration with commercial detergent was the most effective and efficient method for use in skeletal preparation over low heat and concentration, according to Fenton *et al.*, (2003); King and Birch (2015); and Mahon *et al.*, (2021). In addition, simmering in water softens muscles, tendons, and ligaments so that they can be easily removed (Mann and Berryman, 2012). Hot water maceration quickly and effectively clean soft tissue, and the rate of tissue breakdown also increases as the heat increases (Steadman *et al.*, 2006; Maries *et al.*, 2004).

Although Baker *et al.*, (2003) mentioned the difficulty of preparing dry skeletons with biological washing powder (detergent) due to its corrosive nature, but our study postulated that given a maintained temperature of not exceeding 60°C for 3 hours in appropriate concentration (20-30%) and regular monitoring, bones specimens could be cleaned effectively for adequate osteological assessment. Generally, bones are porous and contain a lot of greasy. If not degreased, the bones will turn yellow, leaving a layer of oil over the entire specimen, evoking an unpleasant smell and damaging the bone structure over time through bacterial decay (Baker *et al.*, 2003; Rowley, 2015). To prevent this, the greasy substance must be drawn out from the bone through a bleaching procedure. There are several ways to accomplish this (Gram, 2006; Rowley, 2015). In accordance with our method and results, Greene *et al.*, (1993); Hussain *et al.*, (2007); and Habib and Ali (2019) used a 3% hydrogen peroxide solution for the bleaching purposes. Care must be taken on concentration and timing because results showed that increasing the timing and concentration of Hydrogen peroxide leads to the crumbling of the bones and is also harmful to human skin (Hussain *et al.*, 2007; Rowley, 2015).

Finally, the installed skeleton was mounted in a clean glass house for display in the anatomy lab. The overall procedure took 92 hours (less than 4 days), where cooling and drying were the most time-consuming steps. It consumed 65% (2.5 days) out of

the total time employed in this whole preparation procedure. This similar observation was recorded by **Gofur and Khan (2010) and Atabo et al., (2019)**. We observed the skeleton over six months and there was no decomposition, cracked or crumbling, foul smell, or discoloration of the skeleton (bones) prepared by this technique.

CONCLUSION

There is the possibility of contracting certain zoonotic diseases when handling any part of the carcass of a species commonly associated with rabies, such as dogs, cats, foxes, bats, skunks, and raccoons. For example, the rabies virus can remain viable in the brain tissue of an infected rabid animal until the tissue is completely desiccated. Therefore, it is highly recommended to use latex, rubber, or other gloves when handling any part of the animal carcass.

ACKNOWLEDGMENTS

The authors are grateful to the Department of Anatomy and Histology, Bangladesh Agricultural University, Mymensingh-2202, Bangladesh for the completion of the research work.

Conflict of interest

The authors declare that they are not involved in any potential conflicts of interest.

REFERENCES

- AJAYI, A., EDJOMARIEGWE, O., and ISELAIYE, O. T., 2016.** A review of bone preparation techniques for anatomical studies. *Malaya Journal of Biosciences*, 3(2): 76-80.
- ALLEN, E. R., and NEILL, W. T., 1950.** Cleaning mammal skeletons with mealworms. *Journal of Mammalogy*, 31(4): 464-464.
- ALLOUCH, G. 2014.** Scientific technique for skeletons preservation and preparation of anatomical models to promote veterinary anatomy. *Journal of Veterinary Anatomy*, 7(2): 133-139. <https://doi.org/10.21608/jva.2014.44817>
- ATABO, S. M., HENA, S. A., JAJI, A. Z., and BODINGA, A. H., 2019.** Bovine Skeleton Preparation Using Hot Water Technique for Anatomical Studies. *Asian Journal of Research in Animal and Veterinary Sciences*. 4(3): 1-7.
- BAKER, P., DAVIS, S., PAYNE, S., and REVILL, M., 2003.** On preparing animal skeletons: a simple and effective method. *International Council for Archaeozoology, México*, 4(1): 4-15.
- BEMIS, W. E., HILTON, E. J., BROWN, B., ARRINDELL, R., RICHMOND, A. M., LITTLE, C. D., GRANDE, L., FOREY, P. L., and NELSON, G. J., 2004.** Methods for preparing dry, partially articulated skeletons of osteichthyans, with notes on making ride wood dissections of the cranial skeleton. *Copeia*, 2004(3): 603-609. <https://doi.org/10.1643/C1-03-054R1>
- COUSE, T., and CONNOR, M., 2015.** A comparison of maceration techniques for use in forensic skeletal preparations. *J Forensic Investig*, 3(1): 6.
- FENTON, T. W., BIRKBY, W. H., and CORNELISON, J., 2003.** A fast and safe non-bleaching method for forensic skeletal preparation. *Journal of forensic sciences*, 48(2): 274-276. <https://doi.org/10.1520/JFS2002034>
- GETTY, R., SISSON, S., and GROSSMAN, J. D., 1975.** Sisson and Grossman's the Anatomy of the Domestic Animals. Saunders. Vol 1, 5th Edition, 19 pp.
- GHOSH, R. K. 1998.** Primary veterinary anatomy. Current Books International, Kolkata, pp. 2-3.
- GOFUR, M. R., and KHAN, M. S. I., 2010.** Development of a quick, economical, and efficient method for preparation of skeleton of small animals and birds. *International Journal of BioResearch*, 2(7): 13-17.
- GRAM, C. O. 2006.** Vertebrate Skeletons: Preparation and Storage. National Park Service, pp. 7-11.
- GREENE, E. A., SMITH, K. R., PENDERGRAFT, J. S., RAUB, R. H., and ARNS, M. J., 1993.** Equine skeletal preservation techniques to enhance teaching effectiveness. *Journal of animal science*, 71(8): 2270-2274.
- HABIB, R. S., and ALI, A. S., 2019.** Local Sheep Skeleton Preparation: Development Of A New Preservation Technique. *Journal of Duhok University*, 22(2): 81-84. <https://doi.org/10.26682/ajuod.2019.22.2.8>
- HUSSAIN, M., HUSSAIN, N., ZAINAB, H., and QAISER, S., 2007.** Skeletal preservation techniques to enhance veterinary anatomy teaching. *IJVAMS*, 1: 21-23.
- KARDONG, K. V. 2002.** Vertebrates Comparative Anatomy, Function, and Evolution. International Edition. 3rd Edition. McGraw-Hill Higher Education. New York. USA hal: 233-236 pp.
- KEMPA, K., KULAWIK, M., BARTYZEL, B. J., JAKUBOWSKI, M., SKUBIS, J., and KOCZON, P., 2016.** Characterization of selected techniques of maceration bones of *Gallus gallus domesticus*. *Folia Pomeranae Universitatis Technologiae Stetinensis. Agricultura, Alimentaria, Piscariaet Zootechnica*, 328(39)3: 109-116. <https://doi.org/10.21005/AAPZ2016.39.3.10>
- KING, C., and BIRCH, W., 2015.** Assessment of maceration techniques used to remove soft tissue from bone in cut mark analysis. *Journal of forensic sciences*, 60(1): 124-135. <https://doi.org/10.1111/1556-4029.12582>
- LEEPER, B. J. 2015.** Evaluation of current methods of soft tissue removal from bone. (Doctoral dissertation, University of Pittsburgh ProQuest Dissertations Publishing), pp. 1-128.
- LEIDEN UNIVERSITY LABORATORY FOR HUMAN OSTEOARCHAEOLOGY, 2019.** The skeleton as a source of information. <https://www.universiteitleiden.nl/en/research-dossiers/the-skeleton-as-a-source-of-information>
- MAHON, T. J., MABOKE, N., and MYBURGH, J., 2021.** The use of different detergents in skeletal preparations. *Forensic Science International*, 327: 110967. <https://doi.org/10.1016/j.forsciint.2021.110967>

- MAIRS, S., SWIFT, B., and RUTTY, G. N., 2004.** Detergent: an alternative approach to traditional bone cleaning methods for forensic practice. *The American Journal of Forensic Medicine and Pathology*, 25(4): 276-84.
<https://doi.org/10.1097/01.paf.0000147320.70639.41>
- MANN, R. W., and BERRYMAN, H. E., 2012.** A method for defleshing human remains using household bleach. *Journal of forensic sciences*, 57(2): 440-442.
<https://doi.org/10.1111/j.1556-4029.2011.01987.x>
- OLSON, S. L. 2003.** Development and uses of avian skeleton collections. *Bulletin of the British Ornithologists' Club*. (123A): 26-34.
- PROKOP, P. A., PROKOP, M. A., TUNNICLIFFE, S. D., and DIRAN, C., 2007.** Children's ideas of animals' internal structures. *Journal of Biological Education*, 41(2): 62-67.
<https://doi.org/10.1080/00219266.2007.9656064>
- ROWLEY, B. 2015.** Protocols for Cleaning and Articulating Large Mammal Skeleton. In Symposium (Vol. 2, No. 1, pp. 3).
- SIMONSEN, K. P., RASMUSSEN, A. R., MATHISEN, P., PETERSEN, H., and BORUP, F., 2011.** A fast preparation of skeletal materials using enzyme maceration. *Journal of forensic sciences*, 56(2): 480-484. <https://doi.org/10.1111/j.1556-4029.2010.01668.x>
- SOON, L. P., SEE, K. L., SAIDIN, M. H., HASMI, A. H., MAHMOOD, M. S., ABDULLAH, N. U. R. L. I. Z. A., and AHMAD, N. W., 2015.** Effectiveness of bone cleaning process using chemical and entomology approaches: time and cost. *The Malaysian journal of pathology*, 37(2): 123-135.
- STEADMAN, D. W., DIANTONIO, L. L., WILSON, J. J., SHERIDAN, K. E., and TAMMARIELLO, S. P., 2006.** The effects of chemical and heat maceration techniques on the recovery of nuclear and mitochondrial DNA from bone. *Journal of forensic sciences*, 51(1): 11-17. <https://doi.org/10.1111/j.1556-4029.2005.00001>
- SULLIVAN, L. M., and ROMNEY C. P., 1999.** "Cleaning and preserving animal skulls ."Cooperative Extension, College of Agriculture, The University of Arizona. <http://jan.ucc.nau.edu/~tct/skullprepuofa.pdf> (Accessed 20 July 2022)
- TEFERA, M. 2011.** Enhancing cognitive learning in veterinary osteology through student participation in skeleton preparation project. *Ethiopian Veterinary Journal*, 15(1): 87-102.
- UHRE, M. L., ERIKSEN, A. M., SIMONSEN, K. P., RASMUSSEN, A. R., HJORT, B. B., and LYNNERUP, N., 2015.** Enzymatic maceration of bone: a gentler technique than boiling. *Medicine, Science and the Law*, 55(2): 90-96.
<https://doi.org/10.1177/0025802414532246>
- VANCLEAVE, J. 2010.** How to Prepare a Chicken Skeleton.
<http://scienceprojectideasforkids.com/2010/how-to-prepare-a-chicken-skeleton>. (Accessed 20 May 2022).
- ZANEB, H., and STANEK, C., 2008.** Three Rs in the research and education system of Pakistan: Perspectives and possibilities Proc. 6th World Congress on Alternatives & Animal Use in the Life Sciences August 2007, Tokyo, Japan, (AATEX), 14: 229-233.

How to cite this article:

Ashraf Zaman Faruk and Shonkor Kumar Das, 2023. Detergent Maceration: A Convenient Skeleton Preparation Technique for Teaching and Demonstration of Veterinary Anatomy. *Journal of Applied Veterinary Sciences*, 8 (1): 11– 17.
DOI: <https://dx.doi.org/10.21608/javs.2022.158955.1175>