



Clinical response of dogs affected with transmissible venereal tumor (TVT) to the chemotherapeutic regime with regard to cytomorphology and histopathology

Amal Z. A. Leil¹, Hanaa A. El-Hallawany^{2*} and Howida M. A. Abd El-Rahman¹

¹Field investigation research department, Animal Reproduction Research Institute (A.R.R.I.), Agriculture Research Center, Giza, Egypt.

²Pathology Dept., Animal Reproduction Research Institute (A.R.R.I.), Agriculture Research Center, Egypt.

*Corresponding Authors: Hanaa A. El-Hallawany, E-Mail: hanag2002@yahoo.com

ABSTRACT

Canine transmissible venereal tumor (CTVT) is a contagious neoplasm that is physically transmitted through direct contact with injured skin or mucous. The aim of this study is to investigate the preferable rapid diagnosis and evaluative curing of CTVT with vincristine. Ten cases of transmissible venereal tumours eight bitches and two dogs which had been received for examination at the animal reproduction research institute, agriculture research centre during the time of January 2019 - December 2019. Nine animals showed genital vaginal and penile ulcerative neoplastic masses with bleeding, and one dog suffered from subcutaneous extragenital ulcerative metastatic lesions on the tail, backbone, and inguinal region. Under tranquilizer from the appeared tumor masses, we have taken aspirate and tissue biopsy for cytomorphology, histopathological and immunohistochemical evaluations. For treatment, animals were grouped into two groups according to the size of tumors G1 (size ≤ 100 cm³) and G2 (size > 100 cm³), each group was formed of four females and one male. Fasted animals for 12 hrs. were administrated weakly monotherapy of vincristine intravenously (i/v) with a dose of 0.025 mg/kg body weekly for 4 weeks (G1) and 6 weeks (G2) until total regression. Lymphocytic type recorded in nine genital vaginal and penile tumors, whereas the sole case of extragenital cutaneous revealed plasmacytic type. After 35 days of vincristine remedy, (G1) revealed (100%) total tumor regression while (G2) regressed after three to six weeks without relapse for 6 months. This study verified that; vincristine assessed in complete CTVT tumor regression without relapse within 6 months through its direct stopping outcomes on neoplastic cell proliferation.

Original Article:

DOI: [HTTPS://DX.DOI.ORG/10.21608/JAVS.2022.123900.1132](https://dx.doi.org/10.21608/JAVS.2022.123900.1132)

Received :25 February, 2022.

Accepted :06 April, 2022.

Published in April, 2022.

This is an open access article under the term of the Creative Commons Attribution 4.0 (CC-BY) International License . To view a copy of this license, visit: <http://creativecommons.org/licenses/by/4.0>

Keywords: Canine, Cytomorphology, Vincristine sulfate. Histopathology, Transmissible venereal tumor.

J. Appl. Vet. Sci., 7(2): 58-65.

Canine Transmissible Venereal Tumor (CTVT) is a round-cell tumor of reticuloendothelial origin. Usually, it affects canine genitalia of both sexes and is sexually transmitted but could be extra-genital such as mammary gland, liver, spleen, kidney, and lung (Martins, 2005 ;Gupta and Sood, 2012). CTVT diagnosis is usually done by the physical aspect of the tumor, and confirmed by cytology or histopathology and immunohistochemical (Das and Das, 2000; Ibrahim and Porter, 2012; Ugochukwu *et al.*, 2020).

Cytomorphology is a rapid technique for the diagnosis of TVT, with minimally invasive, painless, and leaving less distortion of cellular morphology than formalin-fixed biopsy samples. Morphology and metastatic behavior of the tumor have been studied

with Amaral *et al.*, (2007) who described three cytomorphological kinds of TVT, which are lymphocytic, plasmacytic, and mixed kind. Progressing tumors whose characterized by higher mast cell counts whereas lymphocytic regressing tumors which containing higher numbers of lymphocytes (Papazoglou *et al.*, 2001 ;Sreekumar *et al.*, 2015).

The most frequently used drug for treatment is vincristine sulfate (Tella, *et al.*, 2004). It is the salt of an alkaloid obtained from the common periwinkle (*Vincarosa livia*); It is achieving 100% cure rate in treated cases even in the early initial progression stages in the presence or absence of metastases (Boscoss and Ververidis, 2004). Vincristine has minimal side effects as well as arresting mechanism on tumor cell

proliferation and mitotic figures (Whitehead, et al., 1980). The aim of this investigation is to prefer rapid diagnosis and evaluative curing of CTVT with vincristine .

MATERIALS AND METHODS

2.1. Animals:

In our work, for examination received at animal reproduction research institute, agriculture research center, ten cases of naturally occurring genital (9) and extragenital (1) canine. Transmissible venereal tumors TVT during the period from (January 2019 - December 2019), eight bitches and two dogs their breeds were German Shepard and Golden Retriever, and petball ith ranged age from 2 to 5 years and a mean bodyweight of 16.5±1.5kg. Under tranquilizer, we took an aspirate from the appeared tumor mass and tissue biopsy for cytomorphology and histopathological exam earlier than, during, and after treatment weekly.

2.2. Physical examination:

2.3. Sonographic evaluations:

Abdominal and pelvic ultrasound for metastases also during and after treatment.

2.4. Chemicals, doses, and concentrations:

- Xylazine tranquilizer (xylaject –ADWIA).
- antihistaminic drug (Avil 45.5mg\2ml i.m., SANOFI).
- Anti-vomiting (primperan 10mg\2ml i.m. SANOFI).
- Vincristine sulfate (Vincracine;EIMC United Pharmaceuticals Badr city Cairo A.R.E) in 2mg/2ml pack was purchased from a veterinary pharmacy. 0.6ml in 60 milliliters (ml) normal saline provided by the manufacturer in a vial to make a final dilution of 0.1mg vincristine sulfate /10ml.

2.4.1 Chemotherapeutic treatment (Administration of Vincristine sulfate):

Animals were classified into two groups according to the neoplasm size G 1 (size ≤ 100 cm³) and G 2 (size > 100 cm³). each group formed of four females and one male.

Before treatment, the animal fasted for at least 12hours and was injected with an antihistaminic drug (Avil 45.5mg\2ml i.m.) and anti-vomiting (primperan 10mg\2ml i.m.). Vincristine sulfate is given to animals at a dosage of 0.025 mg/kg body weight (BW) intravenously once a week in saline fluid therapy 500 ml for a period of 4 weeks (G1). And for 6 weeks (G2). Weekly cytological and clinical examination of each animal of the apparent tumor and any signs to focus the outcome of the medication. These examinations took

place for 35 days and a further 6 months after the complete remission of lesions.

2.5. Pathological examination:

Cytological smears and biopsy were taken from appeared tumour mass underneath tranquilizer as xylazine.

2.5.1. Cytomorphological evaluation:

Cytomorphology using fine-needle aspiration (FNA), is a rapid, field diagnostic technique (Nak et al., 2005; Thangathurai et al., 2008). From the appeared neoplastic growth in the vagina, penis, or on the skin, of the suspected cases of TVT, aspirate was collected using a 2-5 ml syringe then spread onto the slide and stained with methylene blue stain. The cytological preparations were initially evaluated with a 10x objective for the cellularity and cell distribution pattern verification. Then for cell differentiation and to count the cells were analyzed at 400x. and 1000 x, TVT cells were counted on each slide within ten random fields to verify the predominant cell type. They were categorized according to morphology in lymphocytic or plasmacytic as described by Amaral et al., (2007).

2.5.2. Histopathological and Histochemical analysis:

From vaginal and penile appeared tumor tissue masses, as well as cutaneous, specimens, were taken under a tranquilizer. for histopathological confirmation. Then, initially fixed in 10% formalin solution, routinely processed and then stained with hematoxylin and eosin (H&E) and for the detection of collagen and elastic fibers changes tissue sections were stained with Masson-trichrome stain evaluated under light microscopy (Suvarna et al., 2013).

2.5.3. Immunohistochemical evaluation:

Immunohistochemical techniques, Vimentin, P53, desmine had Proceeded according to Marchal et al (1997); Morris et al (2002). Methods were used for immunohistochemical studies, such as streptavidin-biotin peroxidase and streptavidin-biotin alkaline phosphatase. Tissue sections were deparaffinized and rehydrated. Endogenous peroxidase activity was blocked by treatment of the sections with 3% H₂O₂ for a half-hour at room temperature.

After microwave treatment with citrate buffer, pH 6, tissue sections were incubated with 5% powdered milk for half an hour at room temperature. Primary antibodies were used with their specific dilutions. A streptavidin-immunoperoxidase staining technique (Dako) was used for immunolabeling. The immunoreactions were noticed with 3,3`diaminobenzidine substrate (Dako), while was used a streptavidin-biotin alkaline phosphatase method for the vimentin, and the immunoreactions were observed with Permanente Red (DAKO Corp., Carpinteria, CA,

Clinical response of dogs affected with transmissible venereal tumor

Code 0695). Sections were counterstained with the mayor's Hematoxylin.

RESULTS

Table 1: Chemotherapeutic side effects appeared on treated dogs:

| Side effect appeared on treated animal | NO. | % |
|--|-----|------|
| anorexia | 5 | 55.6 |
| diarrhea, | 2 | 22.2 |
| Constipation. | 2 | 22,2 |
| Dermatological alteration | 7 | 77.7 |
| diffuse alopecia | 5 | 55.6 |
| desquamation | 1 | 11.1 |
| hypersensibility reaction. | 1 | 11.1 |

Table 2: Cytomorphology of TVT cells, in ten examined animals:

| | Manifested occurrence | Mitotic figures | biological behavior and metastases | Response to treat. | No. | | % |
|-------------|------------------------------|-----------------|------------------------------------|--|------|--------|-----|
| | | | | | Male | female | |
| Lymphocytic | Genital (vaginal, preputial) | Few | negative | G1: 100% achieved complete remission. G2: 100% achieved complete remission. | 1 | 8 | 90% |
| Plasmacytic | Extragenital (Cutaneous) | Frequent | positive | Dead before vincristine sulfate administration | 1 | | 10% |

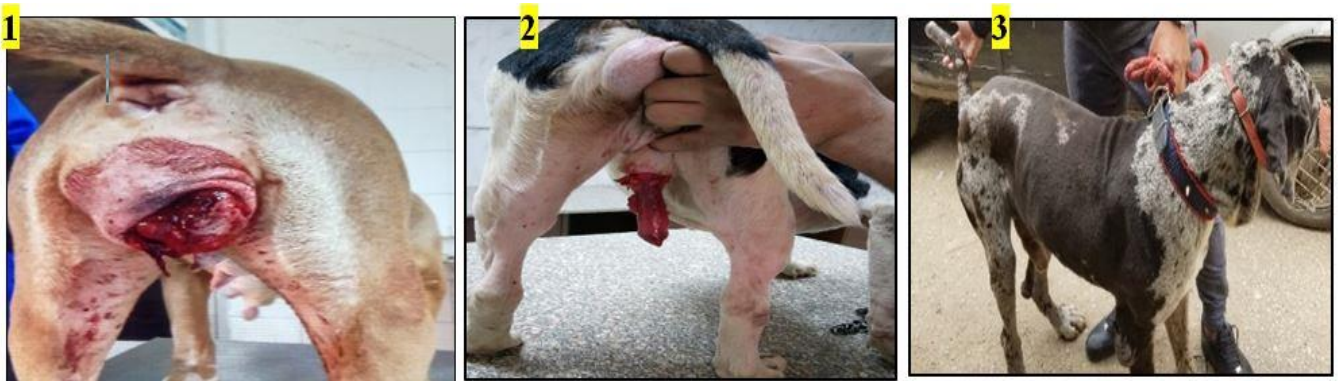

Fig. 1: Bitch showing, hemorrhagic cauliflower-like vaginal genital transmissible venereal tumor protruding from the vulva.

Fig. 2: Male dog showing hemorrhagic cauliflower like a transmissible venereal tumor on the penis.

Fig. 3: Male dog showing multifocal cutaneous plaques oozing serosanguinous discharge,



Fig. 4: Bitch of (G1), showing, and partial remission (PR) first week after administration of vincristine sulfate.

Fig. 5: Bitch of (G1) showing, complete regression (CR) after administration of vincristine sulfate for 4 weeks.

Fig.6a: Cytological smear showing, Lymphocytic type of genital TVT cell sheets (blue arrow), large round neoplastic tvt cells (red arrow) with vacuolated cytoplasm and large round nucleus in between red cells (blue arrow), methylene blue stain., 400X.,

Fig. 6 b: high power of the previous with 1000X.

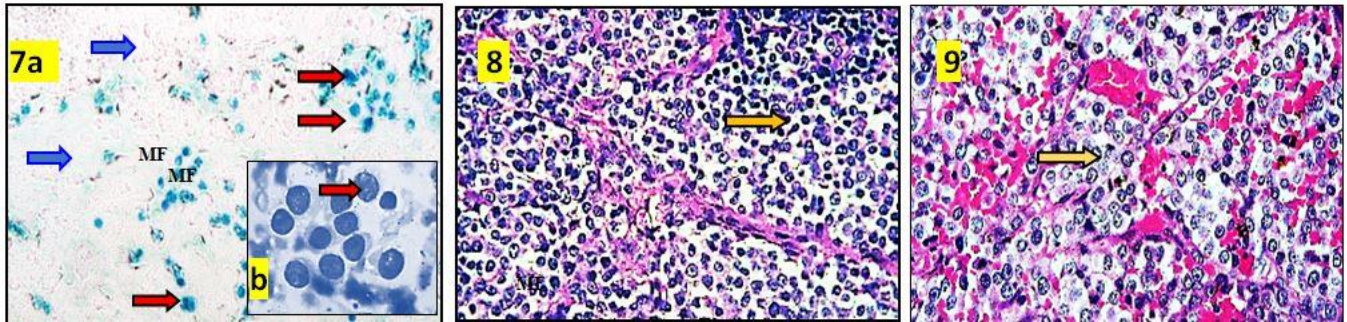


Fig. 7 a: Cytological smear of dog showing, plasmacytic type, large basophilic with granular vacuolated cytoplasm, and large eccentric nucleus (red arrow). with numerous mitotic figures (MF) in between red cells (blue arrow). methylene blue stain., 400X., Fig. 7 b: high power of the previous with methylene blue 1000X.

Fig. 8: Bitch vaginal biopsy of (G1), showing, TVT cell sheets (yellow arrow) supported by thin fibrous connective tissue. With vascular congestion and cellular infiltrations, mainly mature lymphocytes, plasma cells, neutrophils, and macrophages H&E X 10.

Fig. 9: Bitch vaginal biopsy of (G1), showing, large round TVT, spherical nucleus containing nuclei having marginally clumped chromatin (yellow arrow) and few observed Mitoses H&E. x 40.

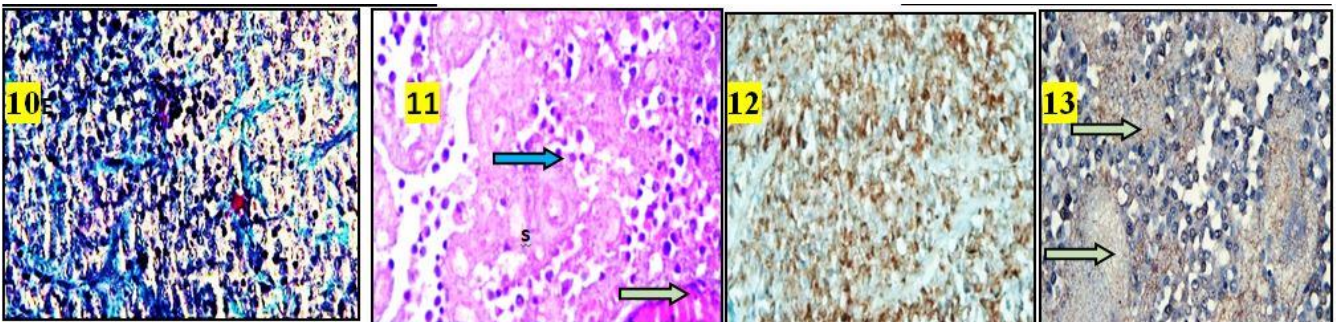


Fig. 10: Bitch vaginal biopsy of (G1), showing, TVT cell sheets intersecting collagen bundles (Masson trichrome). X 10.

Fig. 11: Bitch vaginal biopsy of (G2), showing, regressed tumor cells arrangement (blue arrow) as islands within thick fibrous connective tissue. CT, with the presence of large numbers of lymphocytes, plasma cells, and activated macrophages and apoptosis (green arrow) and fibrosis H&E. x 40.

Fig. 12: Bitch vaginal biopsy of (G2), showing moderate cytoplasmic immunoreactivity of vimentin in almost all neoplastic cells Mayer's hematoxylin counterstain 10X.

Fig. 13: Bitch vaginal biopsy of (G2), showing, strong nuclear P53 positivity in almost neoplastic cells (green arrow); Mayer's hematoxylin counterstain X 40.

DISCUSSION

CTVT usually rapidly proliferates after transplantation (progressive phase P-Phase), forming diffusely arranged round cell sheets that have abundant granular cytoplasm and hyperchromatic pleomorphic nuclei with pronounced large nuclear-cytoplasmic ratio as well as frequent mitotic figures, greater mast cell counts, and few infiltrating lymphocytes (Liao, *et al.* 2003; Gupta and Sood, 2012; Milo and Snead, 2014; Hiblu *et al.*, 2019). This phase is followed by a static phase (stopped cell proliferation) in which round transform to spindle-shaped fibroblasts, infiltrating lymphocytes and more apoptotic cells then may regress spontaneously (stage of regression R-phase). In the initial phase of regression, tumor-infiltrating with macrophages and higher numbers of widely distributed T lymphocytes (TILs) in addition to spindle-shaped cells with intracellular collagen deposition within the

tumor stroma (Yang, 1988; Mukaratirwa *et al.*, 2004; Mukaratirwa *et al.*, 2006; Frampton *et al.*, 2018 ;Ugochukwu *et al.*, 2020).

Physical examination:

Eight cases revealed with examination showed a large vaginal solitary, red, friable, overgrowth that appeared as “cauliflower-like”, protruding from the heavily swollen vulva with noticeable bleeding (Fig.1). One male dog suffered from a neoplastic mass located in the caudal region of the penis (Fig.2). Adding to a solitary case of a male dog showed multifocal cutaneous plaques, oozing serosanguinous discharge, lethargy (Fig.3). Similar findings were reported previously by (Das and Das, 2000; Kabusu *et al.*, 2010; Sreekumar *et al.*, 2015; Awan *et al.*, 2017).

Ultrasonographical evaluations:

Nine cases revealed the presence of a heterogeneous mass in the vaginal canal, extending from the vaginal fornix to the vestibule or inguinal canal without sign metastasis. While abdominal and pelvic metastasis was noticed only in the one cutaneous metastatic case which died before treatment.

Chemotherapeutic treatment:

Vincristine is a natural vinca alkaloid is the most practical effective therapy that provides a CTVT treatment with good outcomes. It has been proved to be a mitotic inhibitor assessing tumor regressing (Özalp *et al.*, 2012; Milo and Snead, 2014; Komnenuo *et al.*, 2015; Fassati, 2018; Abeka, 2019). Early side effects noticed in the treated animals, such as anorexia, diarrhea, dehydration, constipation, and diffuse alopecia were disappeared after complete tumor regression. There were no therapy-related deaths or intensive care requirements.

Dogs with tumor size (≤ 100 cm³) treated successfully with intravenous weekly monotherapy administration of 0.025mg/kg body weight vincristine sulfate, in normal saline, for 4 weeks until complete regression (CR). and disappeared, within 35 days, (Fig.4).(G 2): Dogs with tumor size (> 100 cm³) were treated effectively with three to six weekly monotherapies of vincristine that helped in Partial remission (PR) from the first week of medication. All treated animals achieved 100% complete remission without relapse after 6 months of management. (Fig.5).

As shown in table (1), No changes were recorded in body temperature during the treatment. while some side effects were recorded as a decrease in food intake (five), diarrhea (two), constipation (two), Dermatological alteration (seven), diffuse alopecia (five), desquamation (one), and hyper sensibility reaction (one). These symptoms showed progressive improvement by the end of medication. Our results confirm that I.V medication of vincristine (0.025 mg/kg, once a week for 3-6 weeks) is mostly safe, effective in gradually complete remission with a cure rate reaching 100% of TVT in bitches and dogs without recurrence, through direct effects on tumour cell proliferation and bacterial multiplication. which comes parallel with previously reported by Tella *et al.*, (2004); Ganguly *et al.*, (2016); Setthawongsin *et al.*, (2019); Hiblu *et al.*, (2019); Ugochukwu *et al.*, (2020);Abdelnaby *et al.*, (2021) ; Kumar *et al.*, (2021).

Cytomorphology:

CTVT has three cytomorphological, types they are, plasmacytic, lymphocytic, and mixed type, plasmacytic type considers the malignant metastatic type of TVT (Varaschin *et al.*, 2001; Amaral *et al.*,

2007 ; Setthawongsin *et al.*, 2018), In our study, as shown in table (2) out of ten examined cases, we distinguished nine cases (90%) of Lymphocytic genital type in the form of vaginal and penile genital tumors. In which the predominant cell type was lymphocytes that nearly counted more than 8 at least /field and less plasma cell uniform cellular sheets of large round TVT cells possessed vacuolated, eosinophilic cytoplasm that exhibited large vesicular nuclei with prominent single nucleoli and few mitotic figures (Fig.6a&b). Similar findings were recorded previously by Behera *et al.*, (2012); Mascarenhas *et al.*, (2017) and Ganguly *et al.*, (2016); Alkan *et al.*, (2017).

On the other hand, plasmacytic type in the present study was observed in one case (10%). Cytomorphologically revealed sheets of large TVT cells with vacuolated cytoplasm, eccentric nucleus and fine nuclear chromatin pattern and malignancy signs as many frequent mitotic figures (MF), anisocytosis, anisokaryosis, and increased nuclear: cytoplasmic ratio which suggests the aggressive and metastatic nature. In this case, the predominant cells were (9) plasma cells and a few (4) lymphocytes /fields. Adding to the high population of neutrophils, (Fig. 7a&b) Whereas mixed type morphology was not recorded in our study. Those findings appeared consistent with those previously noticed by Amaral *et al.*, (2007) ; Varaschin *et al.*, (2001);Drumond, *et al.*, (2013); Chowdary *et al.*, (2016);Ugochukwu *et al.*,2020). In this work, frequencies of TVT appeared more in female (80%) than male (20%) dogs. On the other hand, the metastasis anticipated rate in our study turned 10% which is sort of much like the results of MacEwen, (2001) who started from 0 to 17%, while Ferreira *et al.*, (2000), envisioned among 1.5 and 6%.

Histopathological and Histochemical findings:

Macroscopically, most biopsies revealed ulcerating, friable, firm necrotic, hemorrhagic masses, that multi-lobulated cauliflower-like. Microscopically, sections of the biopsy revealed cellular sheets of neoplastic immature lymphocytes in the nodular arrangement that were supported by thin fibrovascular trabeculae exhibited congested vessels with cellular infiltrations, mainly mature lymphocytes, plasma cells, neutrophils, and macrophages (Fig.8). Tumor cells appeared large, round with considerable vacuolated granular cytoplasm and large spherical nucleus. The Nuclei had marginally clumped chromatin with few observed Mitoses (Fig. 9). This supporting fibrovascular trabecula was detected with Masson trichrome stain as blue collagen fibers (Fig. 10). Biopsies taken from regressed tumor masses weekly during a remedy showed a progressive decrease in the size of regressed tumour cells, and the incidence of mitotic figures. Also, noticed a massive infiltration of

lymphocytes, plasma cells, activated macrophages, and neutrophils, as well as observed apoptosis and fibrosis (Fig. 11).

Those findings support the direct immune-mediated role of vincristine sulfate on TVT cells division and proliferation that ceased which results in tumor necrosis (Pia et al., 2011; Carreira et al., 2014; Ganguly et al., 2016) and come parallel with previous findings of (Gonzalez et al., 2000; Tella, 2004; Bates and Eastman 2017; Özalp et al., 2012; Setthawongsin et al., (2019) ;Abdelnaby et al.,2021).

Immune-histochemical evaluation:

Immune-histochemical staining of CTVT reveals that strong cytoplasmic positive reactivity neoplastic cells to vimentin (Fig.12) and Strong nuclear P53 positivity in most of the neoplastic cells (Fig.13), however, were negative for desmin which supports the histiocytic origin of TVT cells Our histopathological and immunohistochemical findings appeared to agree with those defined in genital and extragenital TVT in dogs by Marchal et al., (1997); Mukaratirwa and Gruys (2003); Park et al., (2006); Behera et al., (2012); Gupta and Sood, 2012; Soleimani et al. (2013) ; Milo and Snead, (2014); Leil, et al., (2018); Hiblu et al., (2019); Ugochukwu et al., (2020) ;Abdelnaby et al., (2021).

CONCLUSION

We concluded that, vincristine was found to be the effective chemotherapeutic agent that helps in complete tumor regression via its direct effects on tumor cell division and bacterial multiplication.

Declaration of Conflicting Interests:

The authors revealed that there is no potential conflicts of interest.

REFERENCES

- ABDELNABY, EA., ABOUELELA, Y.S., and YASIN, N.A.E., 2021 . Evaluation of penile blood flow in dogs with tvt before and after chemotherapeutic treatment with special reference to its angioarchitecture. Adv. Anim. Vet. Sci. 9 , (8): 1159-1168. <https://DOI:10.17582/journal.aavs/2021/9.8.1159.116>
- ABEKA,Y.T., 2019. Review on Canine Transmissible Venereal Tumor (CTVT), Canc. Therapy and Oncol. Int. J.; 14, (4).<https://DOI: 10.19080/CTOIJ.2019.14.555895>
- AMARAL, A.S., SILVA, S.B., FERREIRA, I., FONSECA, L.S., ANDRADE, F.H.E., and GASPAS, L.F.J., 2007. Cytomorphological characterization of transmissible venereal tumor. Revista portuguesa de ciências veterinárias. 102: 253-260
- ALKAN, H., SATILMIS, F. ALCIGIR, M.E., KIVRAK, M.B., and AYDIN, I., 2017. Clinicopathological Evaluation of Disseminated Metastases of transmissible Venereal Tumor in a Spayed Bitch. Acta Scientiae Veterinariae. 45, (Suppl 1): 227. <https://DOI: 10.22456/1679-9216.86160>
- AWAN, F., ALI, M.M., MUSHTAQ, M.H., IJAZ, M, CHAUDHRY, M. and AWAN, M., 2017. Identification of Risk Factors for Canine Transmissible Venereal Tumour (CTVT) in owned dogs in Pakistan. Kafkas Univ Vet Fak Derg. 23, (2): 305-310. <https://DOI: 10.9775/kvfd.2016.16507>
- BATES, D., and EASTMAN, A., 2017. Microtubule destabilizing agents: far more than just antimetabolic anticancer drugs. British J. Clin. Pharmacol. 83, (2): 255-268. <https://doi.org/10.1111/bcp.13126>
- BEHERA, S.K., KURADE, N.P., MONSANG, S.W., DAS, D.P., MISHRA, K.K., and MOHANTA, R.K., 2012. Clinico-pathological findings in a case of canine cutaneous metastatic transmissible venereal tumour. Vet Arhiv. 82: 401- 410.
- BOSCO, C.M., and VERVERIDIS, H.N., 2004. Canine TVT: Clinical findings, diagnosis, and treatment. World Small Animal Veterinary Association World Congress Proceedings.
- CARREIRA, V.S., FERRARI, H.F., LANGOHR, I.M., MACKENZIE, C., MONTEZZO, L.C., TAIRA, E., FLOETER-WINTER L.M. and LUVIZOTT ,M.C.R.. , 2014. Leishmania sp. Amastigotes identification in canine transmissible venereal tumour. Case Rep Vet Med. . <http://dx.doi.org/10.1155/2014/603852>.
- CHOWDARY, S.R., CH, M., RAGHUNATH, P.V. SAGAR, B., SAILAJA, P.R., KUMAR, N.V.V. AND KRISHNA , H.,AMARAL, A.S., SILVA, S.B., FERREIRA, I, FONSECA, L.S., ANDRADE, F.H.E., GASPAS, L.F.J. and ROCHA, N.S. , 2016. Cytomorphology of canine transmissible venereal tumors. International Journal of Environment Science, and Technology, Vol. 5, No 4, 2239 – 2244
- DAS, U. ,and DAS, A.K. , 2000. Review of canine transmissible venereal sarcoma. Vet. Res. Commun 24, (8): 545-556. <https://doi.org/10.1023/A:1006491918910>
- DRUMOND, K.O., QUESSADA, A.M., and SILVA, S.M.M.S., 2013. Transmissible Venereal Tumor Treated with Autohemotherapy. Acta Scientiae Veterinariae., 41: 1107.
- FASSATI, A., 2018. What a dog transmissible tumour can teach us about cancer regression. Mol Cell Oncol. 6:5(4):e1472059. <https:// doi: 10.1080/23723556.2018.1472059>.
- FERREIRA, A.J.A., JAGGY, A., VAREJAO, A.P., FERREIRA, M.L.P., CORREIA , J.M.J., MULAS ,J.M., ALMEIDA, O., OLIVEIRA, P., and PRADA, J., 2000. Brain and ocular metastases from a transmissible venereal tumour in a dog. Journal of Small Animal Practice. 41 (4): 165-168. <https:// doi: 10.1111/j.1748-5827.2000.tb03187.x>.
- FRAMPTON, D., SCHWENZER, H., MARINO, G., BUTCHER, L.M., POLLARA, G., KRISTON-VIZI, J., VENTURINI, C., AUSTIN, R. D.E. , CASTRO, K.F., KETTELER, R. , CHAIN, B., GOLDSTEIN, R.A., WEISS, R.A., BECK, S. and FASSATI, A. , 2018. Molecular Signatures of Regression of the Canine Transmissible Venereal Tumor. Cancer cell. 33,(4): 620-633.e6.

- <https://doi:10.1016/j.ccell.2018.03.003>.
- GANGULY, B., DAS, U., and DAS, A.K., 2016.** Canine transmissible venereal tumour: a review. *Vet Comp Oncol.* 14(1): 1-12. [https://doi: 10.1111/vco.12060](https://doi:10.1111/vco.12060)
- GONZALEZ, C.M., GRIFFEY, S.M., NAYDAN, D.K., FLORES, E., CEPDA, R., CATTANEO, G., and MADEWELL, B.R., 2000.** Canine transmissible venereal tumor: a morphological and immune histochemical study of 11 tumors in growth phase and during regression after chemotherapy. *J. Comp. Pathol.*,122, 241-8. <https://doi.org/10.1053/jcpa.1999.0366>.
- GUPTA, K.N., and SOOD, K., 2012.** Pathological and immunohistochemical studies on rare cases of primary extra-genital transmissible venereal tumors in the mammary gland. *Vet. Med.*, 57, (4): 198–206. <https://doi.org/10.17221/5917-VETMED>
- HIBLU, M.A., KHABULI, N.M., and GAJA, A.O., 2019.** Canine transmissible venereal tumour: First report of clinical cases from Tripoli, Libya. *Open Vet J.* 9(2):103-105. <https://doi.org/10.4314/ovj.v9i2.1>.
- IBRAHIM, A.M., and PORTER, B.F., 2012.** Pathology in practice. Transmissible venereal tumor located on the bulbus glandis and body of the penis. *J Am Vet Med Assoc* 241(6):707-709. [https://doi: 10.2460/javma.241.6.707](https://doi:10.2460/javma.241.6.707).
- KABUUSU, R.M., STROUP, D.F., and FERNANDEZ, C., 2010.** Risk factors and characteristics of canine transmissible venereal tumours in Grenada, West Indies. *Vet Comp Oncol.* 8(1):50-55. [https://doi: 10.1111/j.1476-5829.2009.00204.x](https://doi:10.1111/j.1476-5829.2009.00204.x).
- KOMNENOU, A.T., THOMAS, A.L.N., KYRIAZIS, A.P., POUTAHIDIS, T., and PAPAZOGLU, L.G., 2015.** Ocular manifestations of canine transmissible venereal tumour: a retrospective study of 25 cases in Greece. *Vet Rec.* 176(20): 523. [https:// DOI: 10.1136/vr.102968](https://doi:10.1136/vr.102968)
- KUMAR, K., J.H.A. A. K., RAY, K., GAUTAM, A. K., and SINGH, D., 2021.** Diagnosis of TVT with Cell Cytology and Efficacy of Treatment with Vincristine Sulfate in Non- Descriptive Indian Canine Breeds. *Indian Journal of Animal Research.*(55):1352-1355. [https:// DOI: 10.18805/IJAR.B-4175](https://doi:10.18805/IJAR.B-4175)
- LEIL, A.Z.A., EL-HALLAWANY, H. A., FADEL, M.S., ELMESIRY, A., and ELSAYAD, A., 2018.** Electrosurgical Excision and Differential Pathological Diagnosis of External Genital Tumors in Bitch. *AJVS.* Vol. 57, (2): 1-12. [https://DOI:10.5455/ajvs.297573](https://doi:10.5455/ajvs.297573).
- LIAO, K. W., LIN, Z. Y., PAO, H. N., KAM, S. Y., WANG, F. I. and CHU, R. M., 2003.** Identification of canine transmissible venereal tumor cells using in situ polymerase chain reaction and the stable sequence of the long interspersed nuclear element. *Journal of Veterinary Diagnostic Investigation*, 15, 399-406. [https://doi: 10.1177/104063870301500501](https://doi:10.1177/104063870301500501).
- MAC EWEN, E.G., 2001.** Transmissible venereal tumor. In: Winthrow SJ and Mac Ewen EG, eds. *Small Animal Clinical Oncology*. 3rd edition. Saunders, Philadelphia. 651-656.
- MARCHAL, T., CHABANNE, L., KAPLANSKI, C., RIGAL, D., and MAGNOL, J.P., 1997.** Immunophenotype of the canine transmissible venereal tumor. *Vet. Immunol. Immunopathol.* 57(1/2):1- 11. [https://doi.org/10.1016/S0165-2427\(96\)05757-1](https://doi.org/10.1016/S0165-2427(96)05757-1)
- MARTINS, M. M., DE SOUZA, F., FERREIRA, F., and GOBELLO, C., 2005.** The canine transmissible venereal tumor: etiology, pathology, diagnosis and treatment. In P. W. Concannon, G. England, J. Verstegen III & C. Linde Forsberg (Eds.), *Recent Advances in Small Animal Reproduction*. International Veterinary Information Service.
- MASCARENHAS, M.B., PEIXOTO, P.V., RAMADINHA, R.R., ARMIÉN, A.G., COSTA, S.Z., MIRANDA, I.C., NOGUEIRA, V.A. and FRANÇA, T.N., 2017.** Immunohistochemical, lectin histochemical and ultrastructural studies of canine transmissible venereal tumor in Brazil. *Pes Vet Brasil* 37(6): 613-620. [https:// DOI: 10.1590/S0100-736X2017000600014](https://doi:10.1590/S0100-736X2017000600014).
- MILO, J., and SNEAD, E.A., 2014.** Case of ocular canine transmissible venereal tumor. *Canine Vet. J.* 55 (1): 1245-1249.
- MORRIS, J.S., MCINNES, E.F., BOSTOCK, D.E., HOATHER, T.M. and DOBSON, J.M., 2002.** Immunohistochemical and histopathologic features of 14 malignant fibrous histiocytomas from flat-coated retrievers. *Vet. Pathol.* [https://doi: 10.1354/vp.39-4-473](https://doi:10.1354/vp.39-4-473).
- MUKARATIRWA, S., CHIMONYO, M., OBWOLO, M., GRUYS, E. and NEDERBRAGT, H., 2004.** Stromal cells and extracellular matrix components in spontaneous canine transmissible venereal tumour at different stages of growth. *Histol Histopathol.*19:1117–1123. [https:// doi: 10.14670/HH-19.1117](https://doi:10.14670/HH-19.1117).
- MUKARATIRWA, S., CHIWOME, T., CHITANGA, S., and BHEBHE, E., 2006.** Canine transmissible venereal tumour: assessment of mast cell numbers as indicators of the growth phase. *Vet Res Comm.* 30: 613–621. [https://doi: 10.1007/s11259-006-3309-1](https://doi:10.1007/s11259-006-3309-1).
- MUKARATIRWA, S., and GRUYS, E., 2003.** Canine transmissible venereal tumor: cytogenetic origin, Immunophenotype and immunobiology. A review. *J. Vet. Quart.* 25, (3): 101-111. <https://doi.org/10.1080/01652176.2003.9695151>
- NAK, D., NAK, Y., CANGUL, I.T. and TUNA, B., 2005.** A Clinicopathological study on the effect of vincristine on transmissible venereal tumour in dogs. *J Vet Med Physiol Pathol Clin Med.* 52(7): 366-370. <https://doi.org/10.1080/01652176.2003.9695151>
- ÖZALP, G.R., ZIK, B., BASTAN, A., PEKER, S., ÖZDEMİR-SALCI, E.S., and BASTAN, I., 2012.** Vincristine modulates the expression of Ki67 and apoptosis in naturally occurring canine transmissible venereal tumor (TVT). *Biotech. Histochem.* 87 (5): 325- 330. <https://doi.org/10.3109/10520295.2012.655311>
- PAI, C.C., KUO, T.F., MAO, S.J.T., CHUANG, T.F., LIN, C.S. and CHU, R.M., 2011.** Immunopathogenic behaviours of canine transmissible venereal tumour in dogs following an immunotherapy using dendritic/tumour cell hybrid. *Vet Immunol Immunopathol.* 139: 187-199. [https:// DOI: 10.1016/j.vetimm.2010.10.013](https://doi:10.1016/j.vetimm.2010.10.013)
- PAPAZOGLU, L.G., KOUTINAS, A.F., PLEVRAKI, A.G. and TONTIS, D., 2001.** Primary intranasal transmissible venereal tumour in the dog: a retrospective study of six spontaneous cases. *J Vet Med A Physiol Pathol Clin Med.* 48: 391–400. [https:// DOI: 10.1046/j.1439-0442.2001.00361.x](https://doi:10.1046/j.1439-0442.2001.00361.x)

- PARK, M.S., KIM, Y., KANG, M.S., OH, S.Y., CHO, D.Y., SHIN, N.S., and KIM, D.Y. .2006.** Disseminated transmissible venereal tumor in a dog.J. Vet Diagn Invest. 18(1): 130-133.
[https:// DOI: 10.1177/104063870601800123](https://doi.org/10.1177/104063870601800123)
- SETTHAWONGSIN, C., TANGKAWATTANA, S., RUNGSIPIPAT, A., and TECHANGAMSUWAN, S., 2018.** Computerized Cytomorphometric and Cytomorphological Analysis of Canine Transmissible Venereal Tumours. J Comp Pathol. 163:18-22. . [https:// doi: 10.1016/j.jcpa.2018.07.003.](https://doi.org/10.1016/j.jcpa.2018.07.003)
- SETTHAWONGSIN, C., TEEWASUTRAKUL, P., TANGKAWATTANA, S., TECHANGAMSUWAN, S., and RUNGSIPIPAT, A., 2019.** Conventional-Vincristine Sulfate vs. Modified Protocol of Vincristine Sulfate and L-Asparaginase in Canine Transmissible Venereal Tumor Front Vet Sci. 6:300. [https:// doi: 10.1016/j.jcpa.2018.07.003.](https://doi.org/10.1016/j.jcpa.2018.07.003)
- SOLEIMANI, H.S., DEHGHANI, S.N., NAMAZI, F., AHRARI, M. KHAFI, Y., and JALALI, I., 2013.** Electrosurgical Excision of a large uniform Transmissible Venereal Tumor (TVT) in a spayed bitch: a case report J. Anim. Poult Sci. 2 (2): 60-64.
- SREEKUMAR, K.S., NARENDRAN, P.V. and AJIDHAN, V.B., 2015.** Case Study of Canine Transmissible Venereal Tumor. EC Vet Sci 2(2): 109-117.
- SUVARNA, K. S., LAYTON, C. , and BANCROFT, J. D., 2013.** Bancroft's Theory and Practice of Histological Techniques, by Suvarna, 7th Edition Churchill Livingstone.
- TELLA, M.A., AJALA, O.O., and TAIWO, V.O. , 2004.** Complete response of transmissible venereal tumour (TVT) in Nigerian mongrel dogs with vincristine sulfate chemotherapy. African Journal of Biomedical Research. 7: 133-138 .
<https://doi.org/10.4314/ajbr.v7i3.54172>
- THANGATHURAI, R., BALASUBRAMANIAM, GA., DHARMACEELAN, S., BALACHANDRAN, P., SRINIVASAN, P., and SIVASEELAN, S. .,2008.** Cytological diagnosis and its histological correlation in canine transmissible venereal tumor. Vet. Arhiv. 78 (5): 369-376.
- UGOCHUKWU, C. I., AGINA, O. A., OMEKE, J. N., ANEKE, C. I., ADAMU. L. F., AJAYI ,O. L., GIGINYA, N.D., IBRAHIM, C.I., NJOKU, A. SACKEY, K. B. , and IHEDIOHA, J. I., 2020 .**An appraisal of Canine Transmissible Venereal Tumour with emphasis on molecular biology and pathology Iniobong Thai J Vet Med.. 50(1): 1-12.
- VARASCHIN, M.S., WOUTERS, F., BERNINS, V.M.O., SOARES, T.M.P., TOKURA, V.N. and DIAS, M.P.L.L., 2001.** Tumor venereo transmissivel canino na regio de alenas clinico-patologicas. Clin Vet. 6(32): 332-338.
- WHITEHEAD, R., CROWLEY, J. and CARBONE, F., 1980:** cis-Dichlorodiammineplatinum (P), adriamycin (A), cyclophosphamide (C) CCNU (C), and Vincristine (O) (PACCO) combination chemotherapy in advanced non-small cell bronchogenic carcinoma. Proc. Am. Assoc. Cancer Res. 21, 458.
- YANG, T.J., 1988.** Immunobiology of a spontaneously regressive tumor, the canine transmissible venereal sarcoma (review). Anticancer Res 8: 93–95.

How to cite this article:

Amal Z. A. Leil, Hanaa A. El-Hallawany and Howida M. A. Abd El-Rahman, 2022. Clinical response of dogs affected with transmissible venereal tumor (TVT) to the chemotherapeutic regime with regard to cytomorphology and histopathology. Journal of Applied Veterinary Sciences, 7 (2): 58– 65.
DOI: [HTTPS://DX.DOI.ORG/10.21608/JAVS.2022.123900.1132](https://dx.doi.org/10.21608/JAVS.2022.123900.1132)